

Government-run educational institution of higher professional education
Kyrgyz-Russian Slavic University named after B.N. Yeltsin

«ENDORSED BY»

9. 09. 2021 year

HISTOLOGY, EMBRYOLOGY, CYTOLOGY

Course outline (module)

Assigned to **Histology, embryology, cytology**
Academic curriculum 31050150_21_1лд ин.рлх
31.05.01. - PF, 560001 - KR Medical
(for foreign students)
Qualification medical
Mode of study intramural
Total credit value **6 credit points**

Course hours 216
including:
In-class learning 144
Individual work 35,7
exams 35,5

Scope of testing in semesters:
exams 3
credits 2

Course hours scheduling (per semester)

semester (course < Semester on the course)	2 (1.2)		3 (2.1)		total	
	weeks		18			
Type of training	AC	CO	AC	CO	AC	CO
Lectures	18	18	36	36	54	54
Practical	36	36	54	54	90	90
Contact work during the period of theoretical training	0,3	0,3			0,3	0,3
Contact work during the examination session			0,5	0,5	0,5	0,5
Interactive	4	4	5	5	9	9
Total	54	54	90	90	144	144
Face to face learning	54,3	54,3	90,5	90,5	144,8	144,8
Individual work	17,7	17,7	18	18	35,7	35,7
Control			35,5	35,5	35,5	35,5
Total	72	72	144	144	216	216

The course outline developed by:

the head of department associate, cms, docent Kalugina O.P., cms, docent Filipchenko E.G.

Kalugina O.P.

Filipchenko E.G.

Reviewers: the head of department of physics, medical Informatics and biology, cbs, docent Karaeva R.R.

Karaeva R.R.

The course outline

HISTOLOGY, EMBRYOLOGY, CYTOLOGY

Developed in full compliance to FSES 3++:

Federal state educational standards of higher professional education for specialty 31.05.01 Medical (Ministry of science and higher education of the Russian Federation order of 08/12/2020 No. 988)

In accordance with Academic Curriculum:

31.05.01. - PF, 560001 - KR Medical

confirmed by KRSU board of academics 29.06.2021 record № 10.

The course outline endorsed by

histology, embryology, cytology department meeting

Протокол от 17_06 2021 г. № 11


valid for: 2021-27 academic year

The head of department associate Kalugina O.P.

Kalugina O.P.

The course outline endorsed for the academic year

Chairman of the educational and methodological board

6 10 2022 year.

The course outline has been revised, considered and endorsed for implementation in 2022-2023 academic year at the staff meeting of histology, embryology, cytology department

Record of 1 06 2022 year № 11
The head of department associate Kalugina O.P., CBC

**The course outline endorsed for the academic year**

Chairman of the educational and methodological board

_____ 2023 year.

The course outline has been revised, considered and endorsed for implementation in 2023-2024 academic year at the staff meeting of histology, embryology, cytology department

Record of _____ 2023 year № ____
The head of department associate Kalugina O.P., CBC

The course outline endorsed for the academic year

Chairman of the educational and methodological board

_____ 2024 year.

The course outline has been revised, considered and endorsed for implementation in 2024-2025 academic year at the staff meeting of histology, embryology, cytology department

Record of _____ 2024 year № ____
The head of department associate Kalugina O.P., CBC

1. COURSE OUTLINE OBJECTIVES	
1.1	the formation of students' scientific ideas about the microscopic, functional morphology and development of human cellular, tissue and organ systems, the features of the development of the human embryo, the ultramicroscopic level of the structure of the structures of human organs, providing the basis for studying clinical disciplines and contributing to the formation of medical thinking.

2. PLACE OF THE COURSE IN THE EDUCATIONAL PROGRAM	
Educational Program Units:	B 1.0
2.1	Students' Preliminary Training Requirements:
2.1.1	chemistry
2.1.2	biology
2.1.3	anatomy
2.2	Course Units and Practical Sessions imposing the prior Proficiency:
2.2.1	normal physiology
2.2.2	pathological anatomy
2.2.3	pathophysiology, clinical pathophysiology
2.2.4	obstetrics
2.2.5	urology
2.2.6	pediatrics
2.2.7	ophthalmology
2.2.8	phthisiology
2.2.9	oncology, radiation therapy
2.2.10	gynecology
2.2.11	endocrinology
2.2.12	dermatovenereology
2.2.13	general surgery
2.2.14	forensic medicine
2.2.15	faculty therapy
2.2.16	neurology, medical genetics, neurosurgery

3. STUDENTS' COMPETENCIES RESULTING FROM THE COURSE UNIT (MODULE)	
DIC-4: able to use medical devices provided for by the order of medical care, as well as conduct examinations of the patient in order to establish a diagnosis.	
Knowledge:	
Level 1	medical devices provided for by the procedure for the provision of medical care;
Level 2	comparative characteristics of medical devices provided for by the procedures for providing medical care to patients;
Level 3	the use of medical devices provided for by the procedures for providing medical care to patients.
Skills:	
Level 1	determine the scope of medical devices provided for by the procedures for the provision of medical care;
Level 2	conduct a comparative description of medical devices;
Level 3	apply medical devices provided for by the procedures for providing medical care to patients.
Expertise:	
Level 1	skills in identifying medical devices, their scope and the algorithm for using them to provide medical care;
Level 2	skills of comparative characteristics of medical devices and use in standard cases;
Level 3	skills in the use of medical devices provided for by the procedures for providing medical care to patients.

DIC -5: able to assess morphofunctional, physiological conditions and pathological processes in the human body to solve professional problems	
Knowledge:	
Level 1	basic morphofunctional, physiological states and pathological processes in the human body;

Level 2	the specifics of the main morphofunctional, physiological conditions, pathological processes of the human body in comparison;
Level 3	the main ways of differentiation and formulation of the conclusion based on the results of the assessment of morphofunctional, physiological processes and pathological conditions of the patient.
Skills:	
Level 1	reveal the meaning of the main morpho-functional, physiological states and pathological processes in the human body;
Level 2	to compare various morphofunctional, physiological states;
Level 3	note the practical value of specific morphofunctional, physiological processes and pathological conditions of the human body.
Expertise:	
Level 1	skills in determining the main morphofunctional, physiological conditions and pathological processes in the human body;
Level 2	methods of searching and comparing various morphofunctional, physiological states and pathological processes of the human body;
Level 3	skills of assessment, differentiation of the main morphofunctional, physiological and pathological conditions of the human body and their own justification.

As a result of mastering the discipline, the student must

3.1	Knowledge:
3.1.1	the structure of the cell, tissues and organs of a person;
3.1.2	the basic patterns of development and life of the human body based on the structural organization of cells, tissues and organs;
3.1.3	the histofunctional features of tissue elements, methods for their study;
3.1.4	safety rules when working in histological, chemical, biological laboratories with reagents, instruments, animals;
3.1.5	chemical and biological essence of the processes occurring in the human body at the molecular and cellular levels;
3.1.6	general patterns of origin and development of life;
3.1.7	anthropogenesis and ontogeny of man;
3.1.8	functional systems of the human body, their regulation and self-regulation under the influence of environmental factors;
3.1.9	features of reparative and physiological regeneration of organs and tissues.
3.2	Skills:
3.2.1	distinguish features of morphological structures and describe their structure;
3.2.2	work with magnifying equipment (microscopes, optical and simple magnifiers);
3.2.3	to give a histophysiological assessment of the state of various cellular, tissue and organ structures in humans.
3.3	Expertise:
3.3.1	skills in preparation, microscopy and analysis of histological and cytological preparations, analysis of electronic micrographs of human tissues.

4. STRUCTURE AND CONTENT OF THE DISCIPLINE (MODULE)

Activity code	Name of sections and topics / type of lesson /	Semester / Course	Hours	Competencies	Literature	Interact.	Practical training	Note
	Chapter 1. Cytology. Embryology.							
1.1	Cytology. /Lect/	2	2	OPC-4 OPC -5	L1.1 L1.2 L2.1 Э1 Э2 Э3			
1.2	Overview of methods used in histology. Tissue preparation. Microscopy. Histological techniques. /Pr/	2	2	OPC-4 OPC -5	L1.1 L1.2 L2.1 Э1 Э2 Э3			
1.3	Overview of methods used in histology. Tissue preparation. Microscopy. Histological techniques. /SIW/	2	1	OPC-4 OPC -5	L1.1 L1.2 L2.1 Э1 Э2 Э3			

1.4	Cytology. Cell structure. Organoids. Inclusions. /Pr/	2	2	OPC-4 OPC -5	L1.1 L1.2 L2.1 Э1 Э2 Э3			
1.5	Cytology. Cell structure. Organoids. Inclusions. /SIW/	2	1	OPC-4 OPC -5	L1.1 L1.2 L2.1 Э1 Э2 Э3			
1.6	Embryology. /Lect/	2	2	OPC-4 OPC -5	L1.1 L1.2 L2.1 Э1 Э2 Э3			
1.7	Cell's nucleus. Cells cycle. /Pr/	2	2	OPC-4 OPC -5	L1.1 L1.2 L2.1			
1.8	Cell's nucleus. Cells cycle. /SIW/	2	1	OPC-4 OPC -5	L1.1 L1.2 L2.1			
1.9	Progenesis. The sex's cells. The stages of fertilization. /Pr/	2	2	OPC-4 OPC -5	L1.1 L1.2 L2.1 Э1 Э2 Э3	2		Lesson in small groups.
1.10	Embryology. /Pr/	2	2	OPC-4 OPC -5	L1.1 L1.2 L2.1			
1.11	Embryology. /SIW/	2	1,7	OPC-4 OPC -5	L1.1 L1.2 L2.1			
	Chapter 2. General histology.							
2.1	Epithelial tissues. /Lect/	2	2	OPC-4 OPC -5	L1.1 L1.2 L2.1 Э1 Э2 Э3			
2.2	Epithelial tissues. /Pr/	2	2	OPC-4 OPC -5	L1.1 L1.2 L2.1 Э1 Э2 Э3			
2.3	Epithelial tissues. /SIW/	2	1	OPC-4 OPC -5	L1.1 L1.2 L2.1 Э1 Э2 Э3			
2.4	Blood and lymph. Morphological and functional characteristics of formed elements. Hematopoiesis. Theories of hematopoiesis. Myeloid and lymphoid hematopoiesis. /Lect/	2	2	OPC-4 OPC -5	L1.1 L1.2 L2.1 Э1 Э2 Э3			
2.5	Blood and lymph. Morphological and functional characteristics of formed elements. /Pr/	2	2	OPC-4 OPC -5	L1.1 L1.2 L2.1 Э1 Э2 Э3	2		Blood. Hemogram. The lesson is held in an interactive form (cluster).
2.6	Blood and lymph. Morphological and functional characteristics of formed elements. /SIW/	2	2	OPC-4 OPC -5	L1.1 L1.2 L2.1 Э1 Э2 Э3			
2.7	Connective tissues. /Lect/	2	2	OPC-4 OPC -5	L1.1 L1.2 L2.1			
2.8	Connective tissues. /Pr/	2	2	OPC-4 OPC -5	L1.1 L1.2 L2.1			
2.9	Special tissues. /Pr/	2	2	OPC-4 OPC -5	L1.1 L1.2 L2.1			
2.10	Connective tissues. /SIW/	2	2	OPC-4 OPC -5	L1.1 L1.2 L2.1			
2.11	Hematopoiesis. Theories of hematopoiesis. Myeloid and lymphoid hematopoiesis. /Pr//	2	2	OPC-4 OPC -5	L1.1 L1.2 L2.1 Э1 Э2 Э3			
2.12	Hematopoiesis. Theories of hematopoiesis. Myeloid and lymphoid hematopoiesis. /SIW/	2	1	OPC-4 OPC -5	L1.1 L1.2 L2.1 Э1 Э2 Э3			
2.13	Cartilage. Bone. /Lect/	2	2	OPC-4 OPC -5	L1.1 L1.2 L2.1			
2.14	Cartilage/Pr/	2	2	OPC-4 OPC -5	L1.1 L1.2 L2.1			
2.15	Cartilage. /SIW/	2	1	OPC-4 OPC -5	L1.1 L1.2 L2.1			
2.16	Bone. /Pr/	2	2	OPC-4 OPC -5	L1.1 L1.2 L2.1			
2.17	Bone. /SIW/	2	1	OPC-4 OPC -5	L1.1 L1.2 L2.1			
2.18	Muscular. Nervous tissue. /Lect/	2	2	OPC-4 OPC -5	L1.1 L1.2 L2.1			
2.19	Muscular. /Pr/	2	2	OPC-4 OPC -5	L1.1 L1.2 L2.1			
2.20	Muscular. Nervous tissue. /SIW/	2	2	OPC-4 OPC -5	L1.1 L1.2 L2.1			
2.21	Nervous tissue. /Pr/	2	2	OPC-4 OPC -5	L1.1 L1.2 L2.1			
2.22	General histology. /Pr/	2	2	OPC-4 OPC -5	L1.1 L1.2 Э1 Э2 Э3			
2.23	Nervous system. /Lect/	2	2	OPC-4 OPC -5	L1.1 L1.2 Э1			
2.24	Nervous system. /Pr/	2	2	OPC-4 OPC -5	L1.1 L1.2 Э1			
2.25	Nervous system. /SIW/	2	1	OPC-4 OPC -5	L1.1 L1.2 Э1			
2.26	Sensory organs. /Lect/	2	2	OPC-4 OPC -5	L1.1 L1.2 Э1			

2.27	Special senses. The organ of vision. Olfactory organ. /Pr/	2	2	OPC-4 OPC -5	L1.1 L1.2 Э1 Э2 Э3			
2.28	Special senses. The organ of vision. Olfactory organ. /SIW/	2	1	OPC-4 OPC -5	L1.1 L1.2 Э1 Э2 Э3			
2.29	Special senses. The organ of balance. The organ of hearing. The organ of taste. /Pr/	2	2	OPC-4 OPC -5	L1.1 L1.2 Э1 Э2 Э3			
2.30	Special senses. The organ of balance. The organ of hearing. The organ of taste. /SIW/	2	1	OPC-4 OPC -5	L1.1 L1.2 Э1 Э2 Э3			
2.31	General histology. /KpTO/	2	0,3	OPC-4 OPC -5	L1.1 L1.2 Э1 Э2 Э3			
	Chapter 3. Cardiovascular system. Arteries and veins. Microcirculatory blood flow. A heart. Organs of hematopoiesis and immune defense. Central organs (red bone marrow, thymus), structure, functions. Peripheral organs (spleen, lymph nodes), structure, participation in immune reactions. Endocrine system. Central organs-hypophysis. Peripheral organs: thyroid gland, parathyroid gland and adrenal glands.							
3.1	Cardiovascular system. Arteries and veins. Microcirculatory blood flow. A heart. /Lect/	3	2	OPC-4 OPC -5	L1.1 L1.2 Э1 Э2 Э3			
3.2	Cardiovascular system. Arteries and veins. Microcirculatory blood flow. A heart. /Pr/	3	3	OPC-4 OPC -5	L1.1 L1.2 Э1 Э2 Э3			
3.3	Cardiovascular system. Arteries and veins. Microcirculatory blood flow. A heart. /SIW/	3	2	OPC-4 OPC -5	L1.1 L1.2 Э1 Э2 Э3			
3.4	Organs of hematopoiesis and immune defense. Central organs (red bone marrow, thymus), structure, functions. Peripheral organs (spleen, lymph nodes), structure, participation in immune reactions. /Pr/	3	3	OPC-4 OPC -5	L1.1 L1.2 Э1 Э2 Э3			
3.5	Organs of hematopoiesis and immune defense. Central organs (red bone marrow, thymus), structure, functions. Peripheral organs (spleen, lymph nodes), structure, participation in immune reactions. /SIW/	3	2	OPC-4 OPC -5	L1.1 L1.2 Э1 Э2 Э3			
3.6	Endocrine system. Central organs -hypophysis, hypothalamus, epiphysis. /Lect/	3	2	OPC-4 OPC -5	L1.1 L1.2 Э1 Э2 Э3			
3.7	Endocrine system. Central organs -hypophysis, hypothalamus, epiphysis. /Pr/	3	3	OPC-4 OPC -5	L1.1 L1.2 Э1 Э2 Э3			
3.8	Endocrine system. Central organs -hypophysis, hypothalamus, epiphysis. /SIW/	3	1	OPC-4 OPC -5	L1.1 L1.2 Э1 Э2 Э3			

3.9	Cardiovascular system. Arteries and veins. Microcirculatory blood flow. A heart. Organs of hematopoiesis and immune defense. Central organs (red bone marrow, thymus), structure, functions. Peripheral organs (spleen, lymph nodes), structure, participation in immune reactions. Endocrine system. Central organs -hypophysis. Peripheral organs: thyroid gland, parathyroid gland and adrenal glands. /Pr/	3	3	OPC-4 OPC -5	L1.1 L1.2 Э1 Э2 Э3			
3.10	Organs of hematopoiesis and immune defense. Central organs (red bone marrow, thymus), structure, functions. Peripheral organs (spleen, lymph nodes), structure, participation in immune reactions. /Lect/	3	2	OPC-4 OPC -5	L1.1 L1.2 Э1 Э2 Э3			
3.11	Peripheral organs: thyroid gland, parathyroid gland and adrenal glands. /Lect/	3	2	OPC-4 OPC -5	L1.1 L1.2 Э1 Э2 Э3			
	Chapter 4. Digestive system.							
4.1	Digestive system. Tongue. Its development and structure. Salivary glands, structure. /Lect/	3	2	OPC-4 OPC -5	L1.1 L1.2 Э1 Э2 Э3			
4.2	Digestive system. Tongue. Its development and structure. Salivary glands, structure. /Pr/	3	3	OPC-4 OPC -5	L1.1 L1.2 Э1 Э2 Э3			
4.3	Digestive system. Tongue. Its development and structure. Salivary glands, structure. /SIW/	3	2	OPC-4 OPC -5	L1.1 L1.2 Э1 Э2 Э3			
4.4	Teeth. Sources and stages of development. Hard and soft tissues of the tooth, structure. /Pr/	3	3	OPC-4 OPC -5	L1.1 L1.2 Э1 Э2 Э3			
4.5	Teeth. Sources and stages of development. Hard and soft tissues of the tooth, structure. /SIW/	3	2	OPC-4 OPC -5	L1.1 L1.2 Э1 Э2 Э3			
4.6	The structure of the digestive tube. General characteristics. Esophagus, stomach, intestine. /Lect/	3	2	OPC-4 OPC -5	L1.1 L1.2 Э1 Э2 Э3			
4.7	The structure of the digestive tube. General characteristics. Esophagus, stomach, intestine. /Pr/	3	3	OPC-4 OPC -5	L1.1 L1.2 Э1 Э2 Э3			
4.8	The structure of the digestive tube. General characteristics. Esophagus, stomach, intestine. /SIW/	3	2	OPC-4 OPC -5	L1.1 L1.2 Э1 Э2 Э3			
4.9	Liver. Development, structure. The pancreas, development, structure. /Pr/	3	3	OPC-4 OPC -5	L1.1 L1.2 Э1 Э2 Э3			
4.10	Liver. Development, structure. The pancreas, development, structure. //SIW/	3	2	OPC-4 OPC -5	L1.1 L1.2 Э1 Э2 Э3			

4.11	Teeth. Sources and stages of development. Hard and soft tissues of the tooth, structure. /Lect/	3	2	OPC-4 OPC -5	L1.1 L1.2 Э1 Э2 Э3			
4.12	Liver. Development, structure. /Lect/	3	2	OPC-4 OPC -5	L1.1 L1.2 Э1 Э2 Э3			
4.13	The pancreas, development, structure. /Lect/	3	2	OPC-4 OPC -5	L1.1 L1.2 Э1 Э2 Э3			
	Chapter 5. Respiratory system. Airways. Lungs. Alveoli. Air-blood barrier. Skin and its derivatives. Epidermis of “thin” and “thick” skin, layers, calls of derma. Urinary system. Kidneys, development. Nephron, types, structure. Male reproductive system. Development. Structure of testes. Female reproductive system. Development. The structure of the ovaries.							
5.1	Respiratory system. Airways. Lungs. Alveoli. Air-blood barrier. /Lect/	3	2	OPC-4 OPC -5	L1.1 L1.2 Э1 Э2 Э3			
5.2	Respiratory system. Airways. Lungs. Alveoli. Air-blood barrier. /Pr/	3	3	OPC-4 OPC -5	L1.1 L1.2 Э1 Э2 Э3			
5.3	Respiratory system. Airways. Lungs. Alveoli. Air-blood barrier. /SIW/	3	1	OPC-4 OPC -5	L1.1 L1.2 Э1 Э2 Э3			
5.4	Skin and its derivatives. Epidermis of “thin” and “thick” skin, layers, calls of derma. /Pr/	3	3	OPC-4 OPC -5	L1.1 L1.2 Э1 Э2 Э3			
5.5	Skin and its derivatives. Epidermis of “thin” and “thick” skin, layers, calls of derma. /SIW/	3	1	OPC-4 OPC -5	L1.1 L1.2 Э1 Э2 Э3			
5.6	Urinary system. Kidneys, development. Nephron, types, structure. /Lect/	3	2	OPC-4 OPC -5	L1.1 L1.2 Э1 Э2 Э3			
5.7	Urinary system. Kidneys, development. Nephron, types, structure. /Pr/	3	3	OPC-4 OPC -5	L1.1 L1.2 Э1 Э2 Э3	2		Interactive lesson in small groups.
5.8	Male reproductive system. Development. Structure of testes. /Pr/	3	3	OPC-4 OPC -5	L1.1 L1.2 Э1 Э2 Э3			
5.9	Urinary system. Kidneys, development. Nephron, types, structure. /SIW/	3	1	OPC-4 OPC -5	L1.1 L1.2 Э1 Э2 Э3			
5.10	Male reproductive system. Development. Structure of testes. /SIW/	3	1	OPC-4 OPC -5	L1.1 L1.2 Э1 Э2 Э3			
5.11	Female reproductive system. Development. The structure of the ovaries. /Lect/	3	2	OPC-4 OPC -5	L1.1 L1.2 Э1 Э2 Э3			

5.12	Female reproductive system. Development. The structure of the ovaries. /Pr/	3	3	OPC-4 OPC -5	L1.1 L1.2 Э1 Э2 Э3	3		Interactive lesson in small groups.
5.13	The structure of the fallopian tubes, uterus, vagina, mammary glands. Ovarian-menstrual cycle and its regulation. /SIW/	3	1	OPC-4 OPC -5	L1.1 L1.2 Э1 Э2 Э3			
5.14	The structure of the fallopian tubes, uterus, vagina, mammary glands. Ovarian-menstrual cycle and its regulation. /Pr/	3	3	OPC-4 OPC -5	L1.1 L1.2 Э1 Э2 Э3			
5.15	Human embryology. /Lect/	3	2	OPC-4 OPC -5	L1.1 L1.2 Э1			
5.16	Formation, structure and functions of extraembryonic organs. /Lect/	3	2		L1.1 L1.2 Э1 Э2 Э3			
5.17	Human embryology. /Pr/	3	3	OPC-4 OPC -5	L1.1 L1.2 Э1			
5.18	Placenta. /Pr/	3	3	OPC-4 OPC -5	L1.1 L1.2 Э1			
5.19	Skin and its derivatives. Epidermis of "thin" and "thick" skin, layers, calls of derma. /Lect/	3	2	OPC-4 OPC -5	L1.1 L1.2 Э1 Э2 Э3			
5.20	Male reproductive system. Development. Structure of testes. /Lect/	3	2	OPC-4 OPC -5	L1.1 L1.2 Э1 Э2 Э3			
5.21	The structure of the fallopian tubes, uterus, vagina, mammary glands. Ovarian-menstrual cycle and its regulation. /Lect/	3	2	OPC-4 OPC -5	L1.1 L1.2 Э1 Э2 Э3			
5.22	Placenta. /Lect/	3	2	OPC-4 OPC -5	L1.1 L1.2 Э1			
5.23	Respiratory system. Skin and its derivatives. Urinary system. Male reproductive system. Female reproductive system. /Pr/	3	3	OPC-4 OPC -5	L1.1 L1.2 Э1 Э2 Э3			
5.24	Human embryology. /Pr/	3	3	OPC-4 OPC -5	L1.1 L1.2 Э1			
5.25	/КрЭк/	3	0,5					
5.26	/Exam/	3	35,5					

5. ASSESSMENT FUND

5.1. Advancement Questions and Assignments

Questions to check the level of knowledge know:

- cellular organization of living organisms, molecular mechanisms of processes in normal and pathological conditions;
- molecular mechanisms of transport, intercellular interactions, patterns of processes and mechanisms of storage, transmission and use of information in the cell;
- structural and functional organization of genetic material, cytological bases of various forms of reproduction of organisms;
- methods of histological, cytological and embryological studies, basic principles for the manufacture of preparations for light microscopy;
- basics of general embryology, human embryology;
- tissues as systems of cells and their derivatives, the concept of cell populations, determination and differentiation of cells, regularities in the emergence and evolution of tissues, regenerative abilities of tissues;
- general morpho functional characteristics of epithelial, connective, muscle and nervous tissues;
- general morpho functional characteristics of systems and organs

Questions to test the level of knowledge to be able to:

- histological preparations;
- calculation of the leukocyte formula in a blood smear;
- "reading" with the help of a microscope of histological, embryological preparations;
- "reading" histological and embryological microphotographs and drawings corresponding to the indicated preparations;
- sketches of histological and embryological preparations;
- "reading" electron micrographs of cells and non-cellular structures of tissues and organs;
- drawing up a protocol (written and oral description) of the objects under study

Questions to test the level of proficiency in proficiency:
 - development of histological methods in practical classes in the scientific and practical work of a doctor (staining blood smears, sections of tissues and organs, etc.), followed by analysis of manufactured preparations;
 - differential diagnosis of micro preparations and electronic microphotographs used in practical classes;
 - solution of situational problems, requiring the synthesis of knowledge from different sources of information (lectures, textbooks, practical exercises, etc.).

Application 1. Questions for mid-term control (1-6).

Application 2. An example of a ticket to control.

5.2. Course papers themes

Essays are not provided

5.3. Assessment fund

Appendix 3. Situational tasks.

Appendix 4. Tests (demo version).

Appendix 5. Topics of abstracts/reports with a presentation on histology.

5.4. List of assessment tools

Appendix 6. List of types of assessment tools (assessment scales).

6. EDUCATIONAL-METHODOLOGICAL AND INFORMATION SUPPORT OF THE DISCIPLINE (MODULE)

6.1. Recommended reading

6.1.1. Basic Literature

	Authors, compilers	Title	Publisher, year
L1.1	Ross, Michael H. Wojciech Pawlina	Histology: a text and atlas: with correlated cell and molecular biology	Michael H., Ross, - 6th ed., 2011.
L1.2	Laiq Hussain Siddiqui	Medical Histology	Caravan Book Center, Multan Cant, 1999

6.1.2. Additional literature

Authors,	Title	Publisher, year
L2.1	O.P. Kalugina, E.G. Filipchenko, E.V. Sharova, Nazarkul k. A.	Course of lectures on General histology. KRSU, Publishing House, 2021.

6.2. Online resources

Э1	Histology, embryology, cytology	http://med-books.by/
Э2	Histology	https://www.bu.edu/histology/rn/
Э3	Histology	http://basichistology.blogspot.com/2010/01/

6.3. List of Information and Education Technologies

6.3.1 Competence-based Educational Technologies

6.3.1.1	To organize the study of the discipline, traditional educational technologies are used, focused on the communication of knowledge and methods of action, transferred to students in finished form. lecture material is provided to students using multimedia equipment. Traditional educational technologies include: explanatory and illustrative lectures; explanatory and explanatory practical exercises.
6.3.1.2	Innovative educational technologies, interactive classes that form systemic thinking and the ability to generate ideas when solving various situational problems. Innovative educational technologies include reports (abstracts, presentations), the control of which is carried out in the form of independent work in the classroom.
6.3.1.3	Information educational technologies - independent use of computer equipment and Internet resources by a student to perform practical tasks and independent work.

6.3.2. List of Information Reference systems and software	
6.3.2.1	Information and methodological resource - https://vk.com/public192062648 in Russian
6.3.2.2	Information system "Single window of access to educational resources (http://window.edu.ru/).
6.3.2.3	Information system "Single window of access to educational resources (http://window.edu.ru/).
6.3.2.4	Methodological materials on the website of the department (http://gist.krsu.edu.kg) on the university server.
6.3.2.5	Scientific electronic library - http://elibrary.ru/
6.3.2.6	Russian State Library http://www.rsl.ru/
7. COURSE (MODULE) LOGISTICS	
7.1	Theoretical classes are held in lecture-type classrooms for 150 seats.
7.2	Practical classes are held in 5 classrooms for 14 seats each.
7.3	Multimedia complex (laptop, projector).
7.4	Interactive and chalk boards.
7.5	Classroom equipment (microscopes, teaching aids, micro preparations, silent drawings, histology atlases, electronic versions of lectures, textbooks, tables - the microscopic structure of human tissues and organs, educational films).

8. METHODOLOGICAL INSTRUCTIONS FOR STUDENTS ON MASTERING THE DISCIPLINE (MODULE)

<p>Appendix 7. Technological maps of the discipline.</p> <p>Current control (CC).</p> <p>The study of the theoretical part of the discipline is intended not only to deepen and consolidate the knowledge gained in the classroom, but also to contribute to the development of students' creative skills. initiative and organization of their own time.</p> <p>Independent work of the student in the study of the discipline includes:</p> <ul style="list-style-type: none"> - reading the recommended literature and mastering the theoretical material of the discipline; - Familiarity with Internet sources; -preparation for various forms of control (test, test); - work on the design of albums - sketching of micro preparations; - "reading" and description of micro preparations <p>It is better for students to plan the time required for studying disciplines throughout the semester, while providing for regular repetition of the material.</p> <p>The material outlined in the lectures must be regularly worked out and supplemented with information from other sources of literature, presented not only in the program of the discipline, but also in periodicals.</p> <p>When studying the discipline, it is necessary to read the recommended literature for each topic and draw up a brief summary of the main provisions, terms, information that requires memorization and is fundamental in this topic, for the development of subsequent topics of the course. to expand knowledge of the discipline, it is recommended to use Internet resources; conduct searches in various systems and use materials from sites recommended by the teacher.</p> <p>Frontier control (FK).</p> <p>In preparation for the decision of the control work, it is necessary:</p> <ul style="list-style-type: none"> - work out the relevant pages of textbooks, manuals; - use lecture notes or notes from practical material; -read the description of micro preparations and sketch the indicated structures in the album. <p>Tests.</p> <p>When preparing for testing, it is necessary to work out the lecture material and the corresponding pages of study guides (it is desirable to read additional literature).</p> <p>The study of the theoretical part of the discipline is intended not only to deepen and consolidate the knowledge gained in the classroom, but also to promote the development of students' creative skills, initiative and organization of their free time.</p> <p>As part of the study of the discipline, the following types of tasks for independent work are used:</p> <ul style="list-style-type: none"> • independent study of the topic of the theoretical course; •preparation of oral answers to control questions given after each topic; •doing homework; • writing essays; •preparation for practical exercises and tests on micro preparations; •preparation of reports and presentations; •preparation for an interactive lesson; •preparation for test tasks for the assimilation of the material; • solution of situational problems on all topics studied; • performance of drawings in an album. <p>PREPARING A STUDENT FOR A LECTURE. The lecture is the most important form of organization of the educational process:</p> <ul style="list-style-type: none"> - introducing new learning material -explains learning elements that are difficult to understand, - systematizes educational material, - orients in the educational process.
--

In order for a lecture to be productive for a student, it is necessary to prepare for it.

Preparation for the lecture of students is as follows:

- find out the topic of the lecture (according to the thematic plan, according to the information of the lecturer),
- read the study material on the textbook and teaching aids,
- understand the place of the topic being studied in your professional training,
- write down the main terms,
- answer the control questions on the topic of the lecture,
- make clusters and syncwines,
- find out what learning elements remained unclear to you,
- write down the questions that you will ask the lecturer at the lecture.

HOW TO WRITE A LECTURE SUMMARY CORRECTLY

Synopsis (lat. "Conspectus" - review) is a creative process that requires certain skills and abilities.

Tips for taking notes:

1. Do not try to write down verbatim everything that the teacher says - this is impossible. If you strive for this, unfinished sentences, omissions will appear in the notes, which means violations of the logic of the presentation of the material, which will make the summary useless. Learn to write down only the essentials!
2. Learn "by ear" to separate the main position from the secondary. But this does not mean that it is necessary to write down only the main provisions and definitions, which, without examples and illustrations, later, when reading the notes, will be incomprehensible. Therefore, facts and examples are also better reflected.
3. Recordings should be concise, logically connected, be a place like a detailed outline of the lecture.
4. If diagrams, drawings, tables are offered in the lecture, they must be completely entered in the notebook.
5. In the course of the lecture, the teacher usually notes certain thoughts, positions, so immediately make multi-colored notes and various icons, for example: 1 - important, - check, clarify, NB - pay attention.
6. Leave fields in the notebook that can be used later to clarify entries, comments, additions, etc.
7. Use the red line to highlight the semantic parts in the entries.
8. Try to develop your own system of shortening frequently occurring words or replacing them with certain characters. This will give you the opportunity to write less, listen and think more.

situational tasks. Solutions to situational problems are to develop students' skills:

- analyze and systematize educational material;
- integrate the morphophysiological features of parasites and other theoretical material to build diagnostic hypothesis and algorithm of professional actions;
- argumentatively express their point of view;
- listen and consider an alternative point of view;
- work in a team.

PRACTICAL CLASSES Practical classes on the subject of histology are held in specially equipped rooms equipped with microscopes and the necessary equipment for their implementation.

In conducting practical classes, a creative approach of the teacher is necessary in order to improve the quality of students' knowledge. When discussing the content of the topic, it is recommended to use interactive teaching methods (cinquain, cluster, "carousel", "mosaic", Venn diagram).

INTERACTIVE LESSONS. The advantages of an interactive lesson over other types of learning are that the game used, simulating real situations in the future profession, develops the ability to search for and work with information, and can significantly enhance the student's creative abilities.

Visual aids, models, multimedia presentations, educational videos contribute to a better perception of theoretical material, and the solution of test tasks, situational tasks - to consolidate the material covered and develop analytical thinking. The computerization of all spheres of life creates the need to master teaching and controlling computer programs.

DISTANCE LEARNING. For the 2022-2023 academic year, if necessary, it is planned to conduct lectures, practical classes, examinations remotely online using the Internet.

Conducting practical classes on Skype, ZOOM, Google meet resources and Instagram.

Lectures on Skype, ZOOM, Instagram, Google meet.

Checking written homework by exchanging files on free mail resources - the Mail.Ru service (or from a photo via WhatsApp): albums, lecture notebooks, demonstration and description of micro preparations or on the Google classroom platform.

Placement of educational and methodological materials on the resources of the department: <https://vk.com/public192062648> , <http://gist.krsu.edu.kg/> .

The content of distance learning is completed considering the thematic plan.

Questions to mid-term control 1
II semester

1. Cytolemma, structure, function.
2. Cytoplasm, composition, inclusion, types.
3. Endoplasmic reticulum, types, structure of function.
4. Golgi complex, structure, function.
5. Lysosomes, types, structure, functions.
6. Mitochondria, structure, function.
7. Microtubules, structure, function.
8. Ribosomes, types, structure, functions.
9. Centrosome, structure, function.
10. Cilia and flagella, structure of function.
11. Organoids for special purposes: tonofibrils, myofibrils, neurofibrils, microvilli, synaptic vesicles.
12. Cariolemma, structure, functions.
13. Nuclear pores, structure, functions.
14. Core, composition. Nucleolus, structure, functions.
15. Electron-microscopic structure of the chromosome.
16. Interphase. Presynthetic period, G₁.
17. Interphase. Synthetic period, S, duration, function
18. Interphase. Postsynthetic period, G₂ duration, function.
19. Mitosis. Prophase, stages, processes, duration.
20. Mitosis. Metaphase, stages, processes, duration.
21. Mitosis. Anaphase, stages, processes, duration.
22. Mitosis. Telophase, stages, processes, duration.
23. Direct cell division - amitosis, species.
24. Progenesis. Spermatogenesis. Stages.
25. Spermatozoon, structure function.
26. Progenesis. Ovogenesis, stages.
27. Ovum, structure, types.
28. Stages of embryogenesis. Fertilization, stages.
29. Crushing. Types of furrows.
30. Blastula, structure, types.
31. Gastrulation, ways. Gastrula, types, structure.
32. Germ layers, mesoderm differentiation.
33. Extraembryonic organs, amnion, serous membrane, structure of function.
34. Extraembryonic organs, allantois, yolk sac, structure, function.

Questions to Mid-term control2

1. Morphological classification of epithelial tissue.
2. Genetic classification of epithelial tissues (according to N.G. Khlopin).
3. Monolayer uniserial epithelium.
4. Unilamellar multi-row epithelium.
5. Stratified squamous non-keratinizing epithelium
6. Stratified squamous keratinizing epithelium.
7. Stratified transitional epithelium.
8. Classification of simple exocrine glands, structure.
9. Classification of complex exocrine glands, structure.
10. Classification of exocrine glands by the type of secretion, by the nature of the secret.
11. Blood, composition, functions.
12. Development of blood (embryonic hematopoiesis).
13. Red blood cells. Erythrocytopoiesis.
14. Platelets, thrombocytopoiesis.
15. Neutrophilic leukocyte, granulocytopoiesis.
16. Eosinophilic leukocyte, granulocytopoiesis.
17. Basophilic leukocyte, granulocytopoiesis.

18. Monocytes, monocytopoiesis.
19. Lymphocytes, lymphocytopoiesis.
20. Hemogram and leukocyte formula.
21. Classification of proper connective tissue.
22. Loose fibrous irregular connective tissue.
23. Fibroblasts, fibrocytes.
24. Pigment cells, endothelial cells.
25. Lipocytes, reticular cells.
26. Plasmacytes, mast cells.
27. Adventitial cells, pericytes.
28. Macrophages, histiocytes.
29. Collagen, elastic fibers.
30. Connective tissue with special properties.
31. Dense irregular connective tissue.
32. Dense regular connective tissue.

Questions to mid-term control 3

1. Development of cartilage tissue.
2. Chondroblasts, chondrocytes, types.
3. Hyaline cartilage tissue.
4. Elastic cartilage tissue.
5. Collagen fibrous cartilage tissue.
6. Classification of bone tissue.
7. Bone cells.
8. Rough-fibrous bone tissue.
9. Lamellar bone tissue.
10. Direct osteogenesis.
11. Indirect osteogenesis.
12. Age-related changes in cartilage and bone tissue.
13. Histogenetic classification of muscle tissue.
14. Actually smooth muscle tissue, regeneration.
15. Myoepithelial and myoneural muscle tissues.
16. Myogenesis of skeletal muscle tissue.
17. The contractile apparatus of skeletal muscle tissue.
18. Nervous apparatus of skeletal muscle tissue.
19. Trophic apparatus of skeletal muscle tissue.
20. Neuromuscular synapse (motor plaque).
21. Supporting apparatus of skeletal muscle tissue.
22. Specific membrane apparatus of skeletal muscle tissue.
23. Cardiac muscle tissue, regeneration.
24. Development of nervous tissue, stages.
25. Morphofunctional classification of neurons.
26. The structure of neurons.
27. Classification of neuroglia.
28. Ependymal glia, astrocytic glia.
29. Oligodendroglia, microglia.
30. Nerve fibers (fleshy, non-fleshy).
31. Development of myelinated nerve fiber.
32. Morphofunctional classification of nerve endings.

III semester

Questions to mid-term control 4

1. Functions of the nervous system. The source and course of development of the nervous system.
2. The principle of anatomical and physiological division of the nervous system.
3. The structure and regeneration of the peripheral nerve.
4. The structure of the spinal cord. Tissue composition of the spinal cord. Morphological characteristics of neurons and glia of the spinal cord.

5. The structure of the spinal cord. Gray and white matter of the spinal cord.
6. The main centers of the nuclear type of the spinal cord.
7. The structure of the reflex arc.
8. Lining of the wall of the spinal canal and cerebral ventricles.
9. The structure of the cerebellum.
10. The structure of the cerebral cortex.
11. The structure of the membranes of the spinal cord and brain.
12. Embryonic development of the autonomic nervous system.
13. The structure of the autonomic ganglia (extra and intramural).
14. The main neurons of the autonomic nervous system.
15. Classification of the senses.
16. Primary and secondary sensory (neurosensory and sensory-epithelial) cells.
17. The organ of taste, sources and course of embryonic development.
18. Taste buds, structure (receptor and supporting).
19. The organ of balance is the vestibular part of the membranous labyrinth of the inner ear.
20. Static spots and scallops, their structure and function.
21. Cochlear canal of the membranous labyrinth, tissue composition and structure.
22. Corti (spiral) organ, function, structure. Histophysiology of the organ of hearing.
23. Sources of development of the organ of vision.
24. Eyeball, structure, membranes.
25. The structure of the organ of smell.
26. Classification of the cardiovascular system.
27. Stages of vascular development
28. The structure of the capillaries.
29. The structure, classification and types of arteries.
30. The structure, classification and types of veins. Characteristic differences between veins and arteries.
31. The structure of the heart.
32. General characteristics of the hematopoietic organs.
33. Classification of hematopoietic organs and immune defense.
34. The structure and function of the red bone marrow.
35. The structure and function of the thymus.
36. The structure and function of the lymph nodes.
37. The structure and function of the spleen.
38. Classification of the endocrine glands.
39. The structure of the hypothalamus. Characteristics of hormones.
40. Development of the pituitary gland
41. Anterior pituitary gland: chromophobic and acidophilic cells.
42. Basophilic cells of the anterior pituitary gland.
43. The structure of the intermediate and posterior lobes of the pituitary gland.
44. Development of the thyroid and parathyroid glands.
45. The structure of the thyroid gland.
46. The structure of the thyroid gland during normal functioning
47. The structure of true thyroid follicles in hypo- and hyperfunction. Stages of the secretory cycle.
48. The structure of the parathyroid gland.
49. The structure of the adrenal gland.

Questions to mid-term control 5

1. General morphofunctional characteristics of the parts of the digestive system (front, middle, back)
2. Features of the structure of the oral mucosa (lips, cheeks, gums, hard and soft palate).
3. Language, its structure and function.
4. Features of the structure of the mucous membrane of the upper and lower surfaces of the tongue.
5. Classification of the papillae of the tongue, their structure.
6. Salivary glands of the tongue, their classification according to the type of secretion, the nature of the secreted secretion and the structure of the end sections.
7. Large salivary glands.
8. Classification of the salivary glands by location, structure, type of secretion and the nature of the secreted secretion.
9. General plan of the structure of the salivary glands: parotid, submandibular, sublingual.

10. The structure of the parotid gland.
11. Submandibular and sublingual glands, features of their structure.
12. Mucocytes and serocytes.
13. Myoepithelial cells in the salivary glands.
14. Age features of the salivary glands.
15. Sources of development of primary and permanent teeth.
16. The first stage is the laying of tooth germs.
17. The second stage is the differentiation of the tooth germs.
18. The third stage is histogenesis.
 - a) dentin
 - b) pulp
 - c) enamels
 - d) cement
19. Anatomical structure of the tooth
20. Structure, function and chemical composition of dental hard tissues:
 - a) dentin
 - b) enamels
 - c) cement
21. The structure and function of the soft tissues of the tooth: pulp and periodontal.
22. Milk and permanent teeth.
23. Age-related changes in teeth.
24. Sources of development of the digestive tube.
25. Digestive tube, general principle of structure, tissue composition.
26. The structure and significance of the mucous membrane in different parts of the digestive tube.
27. Features of embryonic development of the epithelium of the mucous membrane of the esophagus.
28. The structure of the esophagus wall at different levels.
29. Own and cardiac glands of the esophagus, structure, function.
30. Structural components of the mucous membrane of the skin type. Differences from the mucous membrane of the intestinal type.
31. Sources of development of tissues of the stomach wall.
32. The structure of the stomach wall in different parts (cardiac, fundus, pyloric).
33. Cardiac glands of the stomach.
34. Pyloric glands of the stomach.
35. Local endocrine apparatus of the stomach, structure, function.
36. Serous membranes, tissue composition, structure and function.
37. Intestine, functional significance.
38. Source of development, tissue composition.
39. Small intestine, its departments.
40. Features of the structure of the mucous membrane of the small intestine by department.
41. The structure of the wall 1 2 duodenal ulcer.
42. Duodenal glands, structure, function.
43. The structure of the wall of the jejunum, ileum.
44. Parietal digestion. Crypt-villus system. Functional value.
45. Cellular composition of villous epithelium, structure and function.
46. Cellular composition of crypt epithelium, structure and function.
47. The rectum, the structure of the pelvic and anal wall, its function.
48. Innervation of the colon.
49. Lymphoid apparatus of the large and small intestines. Its value in health and disease.
50. Age-related changes in the wall of the digestive tube.
51. Sources and course of liver development.
52. Liver functions.
53. General plan of the structure of the liver.
54. The structure of the hepatic lobule.
55. Hepatocyte.
56. Bile capillaries.
57. Biliary tract.
58. Features of the blood supply to the liver.

59. Features of the endothelium of intralobular blood capillaries (Kupffer cell).
60. Near-sinusoidal space (Disse), its functions.
61. Liver regeneration.
62. Age-related changes in the liver.
63. Sources and course of development of the pancreas.
64. Functions of the pancreas.
65. General plan of the structure of the pancreas.
66. Acini of the exocrine pancreas.
67. Exocrine pancreaticocytes.
68. Centroacinous cells. Excretory ducts of the exocrine pancreas.
69. Endocrine part of the pancreas.
70. Basophilic and acidophilic insulocytes.
71. Age-related changes in the pancreas.

Questions to mid-term control 6

1. Sources and course of development of the respiratory system.
2. Organs of the respiratory system. General morphological and functional characteristics.
3. Airways of the respiratory system.
4. Trachea. Wall structure, tissue composition.
5. Bronchial tree.
6. The structure of the wall of a large bronchus.
7. The structure of the wall of the middle bronchus.
8. The structure of small bronchi.
9. The structure of the wall of the bronchioles.
10. Respiratory department. Its structural and functional unit is acinus.
11. The structure of the acinus.
12. The structure of the wall of the alveoli.
13. The structure of the air-blood barrier.
14. Lung innervation.
15. Age-related changes in the lungs.
16. Source and course of embryonic skin development.
17. Functions of the skin.
18. Tissue composition of the skin.
19. Epidermis, features of its structure in different parts of the body.
20. The papillary layer and its meaning.
21. Melanocytes.
22. The process of keratinization and its stages.
23. Derma. Its layers and functions.
24. Nerve endings in the skin.
25. Derivatives of the epidermis.
26. Sources and development of sweat and sebaceous glands.
27. The structure and function of sweat glands with merocrine and apocrine types of secretion.
28. The structure and function of the sebaceous glands with a holocrine type of secretion.
29. Hair development.
30. Hair shaft.
31. The structure of the hair root, its tissue composition.
32. External root sheath.
33. Internal root sheath.
34. Hair follicle.
35. Hair bag.
36. Sources and course of development of nails.
37. The nail and its parts.
38. The nail bed and its tissue composition.
39. Nail matrix and its role.
40. Age-related changes in the skin and its derivatives.
41. Sources of development of urinary organs.
42. Stages of embryonic development.
43. General morpho functional characteristics of the organs of the urinary system.

44. Tissue composition of the kidney
45. Cortex and medulla of the kidney.
46. Morpho functional classification of nephrons.
47. The structure of the nephron.
48. The structure of the renal corpuscle.
49. The structure of the capillaries of the renal glomerulus. A wonderful network.
50. Features of the structure of the inner leaflet of the capsule of the renal corpuscle.
51. Pod cytosis. Its structure, functional characteristics.
52. Mesangium, its structure and functional significance.
53. Filtration barrier of the renal corpuscle.
54. Proximal tubule of the nephron.
55. Thin section of Henle's loop.
56. Distal tubule of the nephron.
57. Collecting ducts of the kidney.
58. Juxtglomerular kidney complex, morphological features.
59. Juxtglomerular nephron.
60. Prostaglandin complex.
61. Age features of the kidney.
62. The process of reabsorption in various parts of the nephron.
63. Epithelium of the urinary tract.
64. The structure of the wall of the renal calyces, pelvis and ureters.
65. The structure of the bladder wall.
66. Organs of the male reproductive system.
67. Separation of the reproductive primordia (indifferent stage).
68. Changes in the gonad during the development of the male body.
69. Tissue elements of the developing gonads.
70. Location of primary germ cells and their migration routes.
71. Factors determining the organogenesis of the reproductive system.
72. Testes, general plan of structure and function.
73. The structure of the tunica albuginea and testicular septa.
74. Convoluted and straight tubules, testis network.
75. The structure of the convoluted tubule of the testis.
76. Systematicities (supporting Sertoli cells), their function.
77. Spermatogenesis and its stages.
78. Spermiogenesis.
79. Granulocytes (Leydig interstitial cells), their function.
80. The structure of the wall of the vas deferens.
81. The structure of the vas deferens.
82. The structure of the wall of the seminal vesicle.
83. Prostate gland. Structure and function.
84. Organs of the female reproductive system.
85. Changes in the gonad during the development of the female body.
86. Mullerian ducts and anomalies of their p development.
87. Genitourinary sinus and its derivatives.
88. Ovaries. General plan of structure and function.
89. Ovarian cortex.
90. Oogenesis.
91. The structure of primary and growing follicles.
92. Bubble ovarian follicle (Graaf's vesicle), its structure.
93. Ovulation and factors leading to it. Atretic body.
94. Stages of development of the corpus luteum and its hormonal regulation.
95. Age-related changes in the ovary.
96. Sexual cycle.
97. Types of placentas in different classes of vertebrates.
98. Development and structure, function of the placenta.
99. Determination and differentiation of developmental processes.

Recommended minimum of drawings in the album for delivery of modules on histology, embryology, cytology.

Almazov I.V., Sutulov L.S. Atlas of Histology and Embryology.

II semester

The mid-term control 1

Cytology - № 16, 25, 33, 35, 36, 39, 41, 54

Embryology - № 71, 73, 75, 76, 80, 91, 92, 102 Total: 16 drawings

The mid-term control 2

General histology

Epithelial tissue No. 128, 133, 138, 141, 142

Blood and lymph - No. 151, 152

Hemopoiesis - No. 166

Proper connective tissue - No. 183, 189, 198, 201 (I, II)

Total: 12 drawings

The mid-term control 3

Cartilage tissue - No. 204, 206, 207

Bone tissue - No. 208, 209, 213, 214

Muscle tissue - No. 219, 222, 231

Nerve tissue - No. 244, 267, 268 Total: 13 drawings

In private histology

Nervous system - 287 (A), 289, 298, 316 (A), 327 (photocopy)

Senses - 332, 335, 349, 362

Total: 9 drawings

Total: 50 drawings

III semester

The mid-term control 4

Cardiovascular system - No. 365, 372, 373, 376, 385.

Organs of hematopoiesis and immune defense - No. 391, 395, 400, 592.

Endocrine system - drawings No. 583, 591, 594, 610. A total of 13 drawings

The mid-term control 5

Tongue and large salivary glands - No. 425, 426, 428, 438, 440

Development and structure of teeth - No. 430, 431, 433

Digestive tube - No. 441, 443, 444, 456, 459, 469

Liver and pancreas - No. 471, 478, 479

Total 17 drawings

The mid-term control 6

Respiratory system - No. 498, 503

Leather and its derivatives - No. 403, 411

Excretory system - No. 517, 530, 531

Male reproductive system - No. 536, 543, 548

Female reproductive system (lesson 1) - No. 556, 564

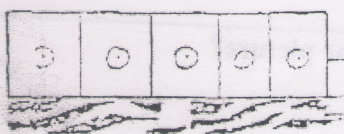
Female reproductive system (lesson 2) - No. 417, 418, 568 (A) A total of 15 drawings

Human placenta - No. 580




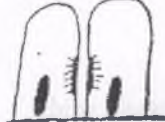



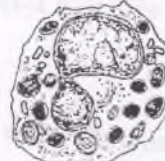



Total: 46 drawings

Variant 4

1. To what histogenetic type does single-layered single-row cylindrical epithelium of the stomach belong?
a) epidermal; b) angioedermal; c) endodermal; d) ependymogial.
2. In the epithelium of cells of different heights, all lie on the basement membrane. What kind of epithelium is this?
a) single-layer single-row prismatic; b) single-layer multi-row prismatic;
c) multilayer transition; d) multilayer squamous non-keratinized.
3. What epithelium is called transitional?
a) turning from flat to prismatic;
b) turning from a non- keratinizing to a keratinizing;
c) turning from the covering epithelium into glandular epithelium;
d) changing the arrangement of cell layers in a stretched and unstretched wall.
4. At what level should the nucleus be located in the epithelial cell?
a) in the center; b) at the basal pole; c) at the apical pole; d) at any of the levels.
5. What exocrine glands are called complex?
a) multicellular, with branched end sections;
b) with alveolar-tubular end sections and unbranched excretory duct;
c) with tubular end sections and an unbranched discharge duct;
d) multicellular, with a branched excretory duct.
6. Which component predominates in the blood plasma?
a) glycosaminoglycans; b) collagen; c) water; d) chondroitin sulfuric acid.
7. What are red blood cells?
a) cell; b) a nuclear-free cell; c) a blood plate; d) a multinucleate cell.
8. What is the average number of white blood cells in an adult healthy person?
a) $6.0-8.0 \times 10^9 / l$; b) $4.0-9.0 \times 10^9 / l$; c) $3.9-5.5 \times 10^{12} / l$; d) $200-300 \times 10^9 / l$.
9. What are the leukocytes responsible for the synthesis of histamine.
a) basophilic leukocyte; b) neutrophilic leukocyte; c) lymphocyte; d) eosinophilic leukocyte.
10. What is a platelet?
a) small oval cell with a large nucleus and a small amount of cytoplasm;
b) denuclearized cell with oxyphilous cytoplasm;;
c) small areas of the cytoplasm, consisting of 2 parts - hyalomer and granulomer;
d) a cell with a segmented 2-lobed nucleus and oxyphilic granules in the cytoplasm.
11. What cells are formed from B-lymphocytes in the peripheral organs of immunogenesis?
a) macrophages; b) plasma cells; c) neutrophils; d) basophils.
12. The cell is spindle-shaped and has winged-like processes. Contains few organelles, the synthesis of collagen and other substances is sharply reduced. Name this cell.
a) fibrocyte; b) smooth muscle cell; c) nerve cell; d) adventitial cell.
13. Determine which cell produces the factors that stimulate the differentiation of T and B-lymphocytes?
a) macrophage; b) monocyte; c) fibroblast; d) basophil.
14. Which cells provide humoral immunity by synthesizing antibodies?
a) neutrophil; b) plasma cell; c) basophil; d) macrophage.
15. What fibers in the center contain an amorphous component, and on the periphery microfibrillar?
a) muscle fiber; b) elastic fiber; c) nerve fiber; d) collagen fiber.
16. Which of the connective tissues is the basis of the organs of hematopoiesis?
a) adipose tissue; b) reticular tissue; c) pigmented tissue; d) mucous tissue.
17. Which of these structures contains elastic fibers, represented by beams I, II and III orders?
a) reticular tissue; b) bone tissue; c) dermis of the skin; d) ligaments.
18. What cells of connective tissue are involved in energy education and water metabolism?
a) fibroblast; b) adventitial cell; c) adipocyte; d) macrophage.



19. What kind of epithelium is represented in the picture?
a) single-layer single-row squamous;
b) single-layer single-row cubic;
c) single-layer single-row cylindrical;
d) single-layer multi-row prismatic.

	<p>20. What kind of epithelium is represented in the picture?</p> <p>a) single-layer single-row cubic; b) single-layer single-row squamous; c) single-layer single-row prismatic; d) single-layer multi-row prismatic.</p>
	<p>21. What kind of epithelium is represented in the picture?</p> <p>a) stratified squamous non-keratinizing; b) stratified squamous keratinizing; c) stratified transitional; d) single-layer multi-row prismatic.</p>
	<p>22. The cell of what kind of tissue is shown in the picture?</p> <p>a) epithelial; b) connecting; c) muscular; d) nervous.</p>
	<p>23. What type of contact between cells is shown in the figure?</p> <p>a) simple; b) desmosome; c) hemidesmosome; d) slit-shaped.</p>
	<p>24. What kind of the gland is represented in the picture?</p> <p>a) simple unbranched tubular; b) simple unbranched alveolar; c) endocrine; d) simple branched alveolar.</p>
	<p>25. What kind of the gland is represented in the picture?</p> <p>a) simple branched tubular; b) simple unbranched tubular; c) compaund branched tubular; d) simple branched alveolar.</p>
	<p>26. What is shown in the picture?</p> <p>a) merocrine type of secretion; b) apocrine type of secretion; c) holocrine type of secretion; d) exocrine type of secretion.</p>
	<p>27. What is shown in the picture?</p> <p>a) eosinophilic granulocyte; b) neutrophilic granulocyte; c) basophilic granulocyte; d) lymphocyte.</p>
	<p>28. What tissue is represented in the picture?</p> <p>a) myeloid; b) lymphoid; c) mesenchyme; d) epithelium</p>
	<p>29. What is shown in the picture?</p> <p>a) labrocyte; b) macrophage; c) adipocyte; d) pericyte.</p>
	<p>30. What is shown in the picture?</p> <p>a) brown adipose tissue; b) white adipose tissue; c) pigmented tissue; d) reticular tissue.</p>

Examples of situational tasks in general histology.

1. In a conditional experiment, in the wall of the yolk sac, at an early stage of embryogenesis, the mesenchyme was experimentally destroyed. There is a violation of tissue development. Which?
2. It is known that the diameter of most erythrocytes is 7.2 microns. Why can red blood cells pass through vessels with a smaller diameter than their own?
3. In judicial practice, traces of the criminal's blood were found at the scene of the crime. The forensic examination concluded that the crime was committed by a woman. What morphological trait in blood cells made it possible to identify the sex of the offender?
4. If a person's blood is taken for analysis soon after performing heavy physical work, then the hemogram will differ from normal. The amount of what shaped elements, in this regard, will change in the blood?
5. The patient was injected into a vein with a hypotonic solution of sodium chloride. What changes can happen to red blood cells? Is it possible to introduce such a solution into the blood?
6. Under the influence of the toxin, the synthesis of fibrinogen is disrupted. What function of the blood will change in this case?
7. A foreign protein has been introduced into the human body. Which blood cells provide an immunological response?
8. An acute purulent inflammatory process has begun in the human body. What changes can be expected in the hemogram?
9. In the patient's leukocyte formula, 45% are neutrophils. What is this condition called?
10. The child was diagnosed with helminthic invasion. What changes in the leukocyte count should be expected?
11. The analysis of the patient's blood revealed a persistent decrease in the number of erythrocytes. What is this phenomenon called?
12. On the preparation of a smear of red bone marrow, a cell with a large acidophilic granularity is visible. The kernel is segmented. Name this cell.
13. On a blood smear preparation, a cell with a basophilic granularity is visible, through which the pinnate nucleus is visible. Name this cell.
14. In a conditional experiment in the red cat's brain, polychromatophilic pro-erythrocytes lack ribosomes and polysomes. What specific protein synthesis will be disrupted?
15. In an experiment on muscles in the early neonatal period, the function of the thymus was inhibited. What type of hematopoiesis will be impaired?
16. In the red bone marrow, the nuclei of maturing erythropoietic cells were marked by autoradiography. In which cells will the label be found?
17. In the tendon collagen fibers are located in one direction, and in the reticular layer of the skin in various directions. How can this be explained?
18. At the site of introduction of a foreign body in the body, inflammation occurs with the participation of blood cells and loose fibrous loose connective tissue. What blood and connective tissue cells will be found in the inflammation focus?
19. When using a light microscope on a preparation of loose fibrous connective tissue, cells are visible: oval, medium-sized, with a large nucleus, chromatin in which is located in the form of a wheel with spokes. The core lies eccentrically. On the electronogram - the granular endoplasmic reticulum and the Golgi complex are very well developed. What are these cells called?
20. A live vaccine has been introduced into the human body. What cells of loose fibrous unformed connective tissue are involved in the development of specific immunity?
21. In loose fibrous unformed tissue, the formation of the basic substance is disturbed. What cells may be impaired by this phenomenon?
22. In humans, with avitaminosis in fibroblasts of loose unformed fibrous tissue of connective tissue, the synthesis of tropocollagen protein is impaired. What changes will be noted in the intercellular substance of this tissue.
23. Skin color has changed under the influence of ultraviolet rays. Which connective tissue cells are involved in this reaction?
24. Cells with basophilic granularity are located around the capillaries in loose fibrous loose connective tissue. What are these cells called, what do they secrete and what is their effect on the functional state of the capillaries?

25. A large number of granules can be seen on the histological specimen next to the tissue basophils. What kind of substance was released from the cells and what is the name of this process?
26. As a result of the introduction of bacteria into the human body, the content of hyaluronidase in the tissues has increased. What is the functional significance of increasing this substance?
27. Two preparations are presented. On the first preparation, elastic cartilage, on the second - hyaline. How can they be distinguished from each other?
28. Cartilage tissue is affected by collagenase. How will cartilage strength change?
29. The gross specimen shows one of the supporting tissues, which lacks the vessels of the microvasculature. What kind of fabric is it?
30. With aging of a person, the content of hyaluronic acid in the cartilage tissue increases. How will the permeability of the cartilage tissue change?
31. On a histological specimen, significant areas of calcification are visible in human cartilage tissue. What is the likely age of the person?
32. Two electron diffraction patterns of cartilage tissue are presented. On the first, there are many mitochondria, on the second - few. Which one belongs to young cartilage?
33. Multinucleated cells containing numerous lysosomes were found in bone tissue. Name these cells and indicate their function?
34. Vitamin C is known to be essential for osteoblast function. How do the properties of bone tissue change when it is lacking?
35. The metaphyseal growth plate is absent on the preparation of human tubular bone. What is the likely age of the person?
36. With premature puberty, ossification of the metaphyseal zones of the tubular bone accelerates. How will this affect the growth of the body?
37. The rats were subjected to physical activity for a month (running in a special apparatus). How will the strength of the bone tissue of the limbs change?
38. Rats were in space flight for a month. How will the content of calcium salts in bone tissue change?
39. An animal with an experimental bone fracture was injected with the hormone calcitonin, which stimulates the function of osteoblasts. How will the injection of calcitonin affect the process of bone regeneration?
40. In smooth muscle tissue, a nerve fiber approaches one cell, and in response a group of 8-10 cells contracts. Explain how the impulse reaches cells that have no contact with the nerve fiber?
41. Of the 3 types of muscle tissue, one forms independent organs and is innervated by the somatic and autonomous systems. Identify this muscle tissue.
42. The cell is epithelial in origin, muscle in function. Name this cell.
43. From the end sections of the salivary glands, the secret enters the excretory ducts under pressure. What cells promote secretion excretion?
44. The electronogram of the muscle cell shows numerous mitochondria with a large number of cristae, the matrix is practically invisible. What muscle tissue cells are characterized by such a structure of mitochondria?
45. The experiment investigates a tissue that contracts tonically and is practically indefatigable. What kind of fabric it is. What part of the nervous system is it innervated by?
46. The electron diffraction pattern of muscle tissue shows deep invaginations of the internal sarcolemma, reaching the myofibrils and fixing them in a certain position. In what muscle tissue are these structures found, their name?
47. There are given preparations of 2 types of striated muscle tissue (skeletal and cardiac). What structural features can distinguish the first from the second?
48. A section of muscle tissue is given. Fusiform cells are visible under the microscope. In the center of the cell there is an elongated rod-shaped nucleus. What kind of muscle tissue is it?
49. Fibers containing many nuclei located along the periphery are visible on a muscle tissue specimen. What kind of muscle tissue is it?
51. In the experiment, the embryo's myocardial plate is destroyed. What tissue development has been impaired?
52. In a conditional experiment on an animal, mesenchymal cells are inhibited. What muscle tissue development disorder can occur?
53. In the early stages of the development of the embryo, the myotome was destroyed in the experiment. What tissue will become impossible to develop?
54. One of the preparations shows a nerve ending surrounded by a connecting capsule. On the other - the capsule is absent; the branching of the axial cylinder is accompanied by lemmocytes. What type are these nerve endings?

55. The diagram shows two types of gliocytes. The first type of gliocytes has numerous processes, the second 2-3 short branching processes. The cells are capable of amoeboid movement. What type of gliocytes are these cellular elements?
56. On a spinal cord specimen, there are two types of gliocytes with numerous processes, differing in size; The 1st type of gliocytes is localized in the gray matter, the 2nd in the white matter. What type of gliocytes are these cellular elements?
57. The nerve fiber is cut. On the specimen, club-shaped extensions of the axial cylinder (growth flasks) were found. Which section of the nerve fiber does the area under study belong to?
58. At the site of the nerve fiber transection, there is a rough connective scar. How will this affect the process of the nerve fiber?
59. Investigated the speed of impulse transmission of various fibers, it was found that the speed of the first 1-2 m / s. What type are they?
60. The preparations show 3 neurocytes: pseudo-unipolar, bipolar and multipolar. How many axons can be identified in each of the listed cells?
61. In the experiment, the animal was subjected to prolonged and excessive pain stimulation. What structural changes will be observed in the chromatophilic substance of motor neurocytes stained according to Nissl, when studied using light microscopy?
62. Two preparations of nervous tissue are presented: on the first in the cytoplasm of neurocytes, a large number of lipofuscin grains is detected, on the second - lipofuscin is absent. What age group do the drugs belong to?
63. In a conditioned experiment, during the development of the neural tube, spongioblasts are destroyed. What kind of neurocytes do the changes occur during further differentiation of the nervous tissue?
64. In the experiment, the ganglion plate was removed from the embryo. What disorders will arise with further differentiation of the nervous tissue?
65. Electron diffraction patterns show two types of neurocytes: I - contains secretory granules in the cytoplasm and neurite, II - only in the axon terminals. What genetic type are these neurocytes?
66. One of the preparations shows a nerve ending surrounded by a connecting capsule. On the other - the capsule is absent; the branching of the axial cylinder is accompanied by lemmocytes. What type are these nervous cells?
67. The cell, located in the ganglion, has a long dendrite going to the intestinal mucosa, where it ends with a receptor, the axon is part of the posterior roots of the spinal cord. The cell is of the pseudo-unipolar type. What is the name of the ganglion? The value of the cell.
68. The defeat of one type of cells of the cerebellum caused irreversible impairment of the function of balance and coordination of movement. Name these cells.
69. On 2 preparations are areas of different parts of the brain. On one, in the thickness of the cortex, pear-shaped cells with 2-3 dendrites are well distinguished, on the other cells, the bodies of which have the shape of a pyramid, 80-120 microns in size. Is it possible to find out which parts of the brain these are?
70. On a histological specimen, an area of the cerebral cortex is seen in the area of the pericentral gyrus (motor centers). Which layers will be the most developed?
71. In the experiment, the cranial part of the neural tube of a 4-week-old embryo was damaged. The differentiation of which organs will be impaired?
72. The reflex arc consists of 3 neurons, which are divided into pre- and postganglionic. Moreover, the cells of postganglionic neurons in the muscle tissue of the organ form terminal plexuses. What arc is this?
73. The ganglion plate was removed from the embryo of the experimental animal. What changes will occur in the development of the embryo?
74. There are nuclei in the gray matter of the spinal cord. Why were these sites called nuclei? Name these kernels.
75. The visual projection area located in the occipital lobes of the brain histologically differs sharply from the motor centers of the cortex. By what histological features in the structure can these two important centers be distinguished?
76. At the early stages of embryonic development in the experiment, the embryo destroyed the trunk section of the neural tube. What are the consequences of this impact?
77. In the gray matter of the spinal cord, nerve cells similar in size, fine structure and functional significance are located in groups. What are these cell clumps called?
78. The child's perception of gustatory stimuli is enhanced. Why?
79. Spinal ganglion cells are affected. Will auditory stimuli be perceived and conducted to the hearing center of the cortex?

80. Two histological preparations of the posterior wall of the eye are presented. On the first preparation, melanin granules are contained in the cytoplasm of the perinuclear zone of the cells of the pigment layer, on the second in their processes. What kind of lighting conditions was the animal in?
81. The electron diffraction pattern shows the retina with a numerous cellular composition, among which there is a supporting cell. What is the name of the retinal supporting cell?
82. A man began to see badly at dusk, and in the light his vision almost did not change. What receptor elements of the retina are impaired?
83. The principle of operation of the hearing aid is based on the enhancement of vibrations of the endolymph of the membranous labyrinth. In what conditions of hearing organ damage is the use of a hearing aid effective?
84. At an appointment with an eye doctor, the patient began to confuse the color of colored objects. "He's probably color blind," thought the doctor. Damage to which cells of the retina of the eye leads to this disease?
85. As a result of the accidental use of acetic acid, the taste buds of the anterior part of the tongue atrophied in the patient. What gustatory irritations are lost in this case? Bitter or Sweet? Which papillae of the tongue are damaged?
86. The patient's vision deteriorated due to a change in the refraction of the lens. In what area of the retina must the rays of light fall in order for it to see well again?
87. Upon entering the aviation school, 2 applicants, after rotating them in a chair, could not walk well along the path. Which cells of the vestibular apparatus are impaired?
88. Dogs detect objects by smell, the range of which is very large. What do you think is the reason?
89. The doctor found a complete hearing loss in the patient. Which cells of the organ of Corti are affected in this case?
90. A patient's hearing has sharply deteriorated after suffering an inflammation of the middle ear. Why did this happen?
91. The patient has a broken eardrum integrity. Explain why your hearing has deteriorated?

Tests (demo version)

1. What are the main chemical components included in the composition of the cell membrane

- 1) glycogen, proteins, polysaccharides
- 2) phospholipids, proteins, polysaccharides
- 3) phospholipids, acids, polysaccharides
- 4) proteins, acids, polysaccharides

2. What are the structural elements of the cytoplasm?

- 1) Organoids, cytolemmas, hyaloplasms
- 2) inclusions, nucleus, hyaloplasm
- 3) organelles, inclusions, hyaloplasm
- 4) cytolemin, nuclei, inclusions

3. What general purpose organelles have a membrane structure?

- 1) endoplasmic reticulum
- 2) microtubules
- 3) centrosome
- 4) ribosomes

4. What general purpose organelles have a non-membrane structure?

- 1) Golgi complex
- 2) mitochondria
- 3) ribosomes
- 4) lysosomes

5. Identify a special purpose organoid

- 1) Golgi complex
- 2) microvilli
- 3) microtubules
- 4) mitochondria

6. What general-purpose organoid is the energy source in the cell?

- 1) mitochondria
- 2) microtubules
- 3) misosomes
- 4) ribosomes

7. Which general purpose organoid has two membranes?

- 1) lysosomes
- 2) Golgi complex
- 3) mitochondria
- 4) endoplasmic reticulum

8. What is the chemical composition of ribosomes?

- 1) 80% protein, 20% RNA

- 2) 60% protein, 40% RNA
- 3) 40% protein, 60% RNA
- 4) 20% protein, 80% RNA

9. What is the function of ribosomes in cells?

- 1) synthesis of fats
- 2) synthesis of carbohydrates
- 3) protein synthesis
- 4) synthesis of polysaccharides

10. Determine the centriole formula

- 1) $(9 \times 3) + 0$
- 2) $(9 \times 2) + 2$
- 3) $(8 \times 3) + 1$
- 4) $(9 \times 3) + 1$

11. What is the structure of microtubules?

- 1) a cylinder, the wall of which is formed of 13 molecules of myosin protein
- 2) a cylinder, the wall of which is formed of 13 molecules of actin protein
- 3) a cylinder, the wall of which is formed of 13 molecules of the protein tubulin
- 4) a cylinder, the wall of which is formed of 13 molecules of the protein elendin

12. What elements of cells are called inclusions?

- 1) unstable accumulations of substances in the hyaloplasm
- 2) unstable accumulations of substances in the karyoplasm
- 3) constant accumulations of substances in the hyaloplasm
- 4) constant accumulations of substances in the karyoplasm

13. What structural elements form the core:

- 1) hyoplasm, organelles, cytoplasm
- 2) karyoplasm, chromatin, nucleolus
- 3) organelles, nucleolus, inclusions
- 4) chromatin, hyoplasm, karyolemma

14. Determine the formula of nuclear pores:

- 1) $(9 \times 3) + 0$
- 2) $(9 \times 2) + 2$
- 3) $(8 \times 3) + 1$
- 4) $(8 \times 3) + 0$

15. Indicate the components of nuclear pores

- 1) supporting, granular
- 2) fibrillar, granular
- 3) trophic, granular
- 4) membrane, grvnular

16. What structural elements of the cell provide for protein synthesis?

- 1) Golgi complex, smooth endoplasmic reticulum
- 2) mitochondria, microtubules
- 3) ribosomes, granular endoplasmic reticulum
- 4) lysosomes, ribosomes

17. What cell organelles provide the synthesis of carbohydrates and lipids?

- 1) Golgi complex, smooth endoplasmic reticulum
- 2) mitochondria, microtubules
- 3) ribosomes, granular endoplasmic reticulum
- 4) lysosomes, ribosomes

18. What process leads to the formation of two cells with an equal diploid set of chromosomes?

- 1) meiosis
- 2) mitosis
- 3) amitosis
- 4) phagocytosis

19. How old, damaged cells divide?

- 1) mitosis
- 2) amitosis
- 3) meiosis
- 4) phagocytosis

20. What is the mitotic cycle?

- 1) prophase, interphase
- 2) metaphase, interphase
- 3) mitosis, interphase
- 4) amitosis, interphase

21. Identify a cell that is capable of synthesizing fibrillar proteins (collagen, elastin).

- 1) plasmacyte
- 2) fibrocyte
- 3) fibroblast
- 4) lipocyte

22. Which cell is involved in the formation of the basic substance and fibers?

- 1) mast cell
- 2) fibroblast
- 3) fibrocyte
- 4) pericyte

23. Which cell is capable of synthesizing a biologically active substance (pyrogen) that increases body temperature during inflammation?

- 1) fibroblast
- 2) fibrocyte
- 3) plasmacyte
- 4) macrophage

24. Name a cell that transmits antigenic information to lymphocytes:

- 1) monocyte
- 2) erythrocyte
- 3) macrophage
- 4) plasmacyte

25. Determine which cell produces factors that stimulate the differentiation of lymphocytes?

- 1) macrophage
- 2) monocyte
- 3) fibrocyte
- 4) fibroblast

26. Name the cell where the nucleus is located eccentrically, near the nucleus there is a light zone - "Light courtyard".

- 1) lipocyte
- 2) fibrocyte
- 3) plasmacyte
- 4) mast cell

27. What cells provide humoral immunity by synthesizing antibodies?

- 1) lipocyte
- 2) plasmacyte
- 3) fibrocyte
- 4) mast cell

28. Name a cell in the cytoplasm of which there are many granules with a reticular, lamellar, crystalloid and mixed structure.

- 1) lipocyte
- 2) plasmacyte
- 3) fibrocyte
- 4) mast cell

29. Indicate which cell has a spherical shape, the nucleus is located sharply eccentrically in the form of a crescent moon, the center is occupied by a large drop of triglycerides.

- 1) lipocyte
- 2) plasmacyte
- 3) fibrocyte
- 4) mast cell

30. What cells of connective tissue are involved in trophism?

- 1) plasmacyte
- 2) fibrocyte
- 3) lipocyte
- 4) mast cell

31. Determine the cell that regulates local homeostasis.

- 1) plasmacyte

- 2) fibrocyte
- 3) lipocyte
- 4) mast cell

32. Name a cell, the cytoplasm of which contains the substance melanin?

- 1) plasmacyte
- 2) pigment cell
- 3) lipocyte
- 4) mast cell

33. What fibers in the center contain an amorphous component, and on the periphery - microfibrillar?

- 1) collagenfiber
- 2) reticular fiber
- 3) elastic fiber
- 4) nerve fiber

34. Identify connective tissue with special properties that is found only in the fetus

- 1) pigment tissue
- 2) reticular tissue
- 3) adipose tissue
- 4) mucous tissue

35. What connective tissue is presented in its structure by bundles of collagen fibers, called bundles of the first, second, third and fourth orders.

- 1) loose fibrous loose connective tissue
- 2) dense fibrous unformed connective tissue
- 3) dense fibrous formed connective tissue
- 4) reticular tissue

36. Indicate the connective tissue with special properties:

- 1) dense fibrous unformed
- 2) dense fibrous decorated
- 3) pigmented
- 4) loose fibrous unformed

37. Which connective tissue with special properties is the stroma of the hematopoietic organs?

- 1) pigmented
- 2) reticular
- 3) mucous
- 4) fat

38. Which connective tissue with special properties protects the body from exposure to sunlight?

- 1) pigmented
- 2) reticular
- 3) mucous
- 4) fat

39. What organs are the reticular tissue in?

- 1) leather
- 2) bone marrow
- 3) intestines
- 4) heart

40. Which organs are the dense fibrous formed connective tissue part of?

- 1) leather
- 2) skeletal muscle
- 3) tendons
- 4) bone marrow

41. Source of blood development:

- 1) ectoderm
- 2) endoderm
- 3) mesoderm
- 4) mesenchyme

42. Percentage of plasma in blood:

- 1) 30%
- 2) 40%
- 3) 60%
- 4) 90%

43. Percentage of blood corpuscles:

- 1) 30%
- 2) 40%
- 3) 60%
- 4) 90%

44. Percentage of water in blood plasma:

- 1) 30%
- 2) 40%
- 3) 60%
- 4) 90%

45. Percentage of blood plasma dry matter:

- 1) 10%
- 2) 30%
- 3) 40%
- 4) 60%

46. What proteins are blood plasma proteins:

- 1) collagen
- 2) elastin
- 3) fibrinogen
- 4) rhodopsin

47. What are erythrocytes?

- 1) cage
- 2) a nuclear-free cell
- 3) plate of blood
- 4) multi-core cell

48. What are the components of erythrocytes?

- 1) core
- 2) organelles
- 3) inclusions
- 4) organelles for special purposes

49. What protein is included in erythrocytes?

- 1) albumin
- 2) globulin
- 3) fibrinogen
- 4) hemoglobin

50. Most red blood cells are in the form:

- 1) sickle
- 2) double-concave
- 3) double-convex
- 4) branch

51. From which cells are platelets formed directly:

- 1) from promyelocytes
- 2) from normocytes
- 3) from megakaryocytes
- 4) from metamyelocytes

52. What cells of the neutrophilic series normally enter the bloodstream?

- 1) myelocytes
- 2) metamyelocytes
- 3) stab leukocytes
- 4) segmented leukocytes

53. What is a platelet?

- 1) cage
- 2) a nuclear-free cell
- 3) platelet
- 4) multi-core cell

54. Name a cell common to cells of the myeloid lymphoid series:

- 1) megakaryoblast
- 2) proerythroblast

- 3) promyelocyte
- 4) stem pluripotent blood cell

55. What cells do monocytes differentiate into?

- 1) into macrophages
- 2) into plasma cells
- 3) into lymphocytes
- 4) into lipocytes

56. What is the percentage of neutrophils from the total number of leukocytes?

- 1) 0.5-1%
- 2) 2-5%
- 3) 6-8%
- 4) 65-75%

57. What is the percentage of reticulocytes in the peripheral blood?

- eleven%
- 2) 5%
- 3) 8%
- 4) 65%

58. What is the percentage of eosinophils from the total number of leukocytes?

- 1) 0.5-1%
- 2) 2-5%
- 3) 6-8%
- 4) 65-75%

59. What is the percentage of basophils from the total number of leukocytes?

- 1) 0.5-1%
- 2) 2-5%
- 3) 6-8%
- 4) 65-75%

60. What is the percentage of monocytes from the total number of leukocytes?

- 1) 0.5-1%
- 2) 2-5%
- 3) 6-8%
- 4) 65-75%

61. The source of development of which muscle tissue is the mesenchyme?

- 1) smooth muscle tissue
- 2) cardiac muscle tissue
- 3) skeletal muscle tissue
- 4) myoepithelial muscle tissue

62. What muscle tissue develops from the mesoderm splanchnotome?

- 1) smooth muscle tissue
- 2) cardiac muscle tissue
- 3) skeletal muscle tissue
- 4) myoepithelial muscle tissue

63. What muscle tissue develops from the mesoderm somites?

- 1) smooth muscle tissue
- 2) cardiac muscle tissue
- 3) skeletal muscle tissue
- 4) myoepithelial muscle tissue

64. Which of the following muscle tissues develops from the cutaneous ectoderm?

- 1) smooth muscle tissue
- 2) cardiac muscle tissue
- 3) skeletal muscle tissue
- 4) myoepithelial muscle tissue

65. The source of development of which muscle tissue is myoneural tissue?

- 1) smooth muscle tissue
- 2) cardiac muscle tissue
- 3) skeletal muscle tissue
- 4) myoepithelial muscle tissue

66. What are the connections in smooth muscle tissue that provide functional interactions of myocytes in the tissue?

- 1) desmosome
- 2) simple connection
- 3) nexus
- 4) by the type of castle

67. In what muscle tissues does physiological regeneration take place in the form of compensatory hypertrophy?

- 1) smooth muscle tissue
- 2) skeletal muscle tissue
- 3) myoepithelial muscle tissue
- 4) myoneural muscle tissue

68. Identify the cells of muscle tissue, if they are located in the glands, have a stellate shape, The new apparatus is located in the processes.

- 1) cardiomyocytes
- 2) myoepithelial cells
- 3) myocytes
- 4) myosimplasts

69. In what muscle tissue are satellites involved in regeneration found?

- 1) skeletal muscle tissue
- 2) cervical muscle tissue
- 3) smooth muscle tissue
- 4) myoepithelial muscle tissue

70. In what muscle tissue is the fiber formed by symplast and satellite cells the main element?

- 1) smooth muscle tissue
- 2) skeletal muscle tissue
- 3) cardiac muscle tissue
- 4) myoepithelial muscle tissue

71. What form do contractile cardiomyocytes have?

- 1) fusiform
- 2) star shape
- 3) oval shape
- 4) rectangular shape

72. What cell of muscle tissue has a cylindrical shape, the nucleus is in the center, mitochondria are well developed and the cells are interconnected by intercalated discs?

- 1) myocyte
- 2) cardiomyocyte
- 3) myoepithelial cell
- 4) satellite

73. What muscle tissue contains myofibrils with transverse striation?

- 1) skeletal muscle tissue
- 2) smooth muscle tissue
- 3) myoepithelial muscle tissue
- 4) myoneural muscle tissue

74. What electrolytes are involved in the histophysiology of muscle tissue contraction?

- 1) sodium ions
- 2) potassium ions
- 3) calcium ions
- 4) chlorine ions

75. In what muscle tissues are deep invaginations, called T-tubes, into which the basement membrane enters?

- 1) skeletal muscle tissue
- 2) smooth muscle tissue
- 3) myoepithelial muscle tissue
- 4) cardiac muscle tissue

76. What muscle tissue contracts slowly, tonically and practically indefatigably?

- 1) heart
- 2) skeletal
- 3) smooth
- 4) myoneural

77. In which tissues there are layers of connective tissue bearing the following names: endomysium, perimysium and epimysium?

- 1) nervous tissue

- 2) muscle tissue
- 3) bone tissue
- 4) cartilage

78. Identify the tissue in which the areas between the two telophragms meet, called sarcomeres:

- 1) smooth muscle tissue
- 2) skeletal muscle tissue
- 3) bone tissue
- 4) cartilage tissue

79. Smooth muscle tissue is part of the following organs:

- 1) adrenal gland
- 2) the brain
- 3) intestines
- 4) heart

80. In the structural and functional units of muscle tissue, there is an organoid of special significance:

- 1) myofibrils
- 2) neurofibrils
- 3) tonofibrils
- 4) flagella

81. Neurons develop from:

- 1) mesenchyme
- 2) mesoderm
- 3) endoderm
- 4) neural tube

82. The source of development of which neuroglia is the mesenchyme?

- 1) ependymoglia
- 2) astroglia
- 3) microglia
- 4) oligodendrogia

83. The marginal veil in the developing neural tube consists of:

- 1) neurons
- 2) processes of neurons
- 3) macroglia
- 4) microglia

84. Neurofibrils in a neuron perform the function:

- 1) protective
- 2) trophic
- 3) support
- 4) conduction of the impulse

85. The following takes part in the conduction of nervous excitement through nerve cells:

- 1) neurofibrils
- 2) synaptic vesicles
- 3) lysosomes
- 4) ergastoplasm

86. The structures of the myelin sheath of the nerve fiber are presented:

- 1) ependymocytes
- 2) astrocytes
- 3) oligodendroglia
- 4) microglia

87. At the heart of the regeneration of nerve fibers, the main role belongs to:

- 1) microglia
- 2) ependymocytes
- 3) astrocytes
- 4) oligodendroglia

88. How many axons does a multipolar neuron have?

- 1) one
- 2) two
- 3) three
- 4) four

89. How many dendrites does a pseudo-unipolar neuron have?

- 1) one
- 2) two
- 3) three
- 4) four

90. In a neuron, a tigroid is represented by the structure:

- 1) Golgi apparatus
- 2) granular endoplasmic reticulum
- 3) neurofibrils
- 4) synaptic vesicles

91. A coarse connective tissue scar has developed at the site of the nerve fiber transection. How will the regeneration of the nerve fiber go?

- 1) regeneration is accelerated
- 2) regeneration is slowed down
- 3) there will be no regeneration
- 4) normal recovery

92. The preparation shows a branched receptor, surrounded by lemmocytes and a capsule. Name the receptor:

- 1) free nerve ending
- 2) bushy nerve ending
- 3) non-free non-encapsulated nerve ending
- 4) non-free incasulated nerve ending

93. The presence of what special-purpose organelles determines the neuron?

- 1) cilia
- 2) synaptic vesicles
- 3) microvilli
- 4) myofibrils

94. Muscle spindles by functional type are related to:

- 1) motor
- 2) associative
- 3) sensitive
- 4) neurosecretory

95. The neuroglia that forms the inner lining of the ventricles of the brain is called:

- 1) ependymocyte
- 2) astrocyte
- 3) oligodendroglia
- 4) microglia

96. Neuros of autonomic ganglia develop from:

- 1) entodermis
- 2) mesoderm
- 3) neural tubes
- 4) ganglion plates

97. Name the areas of myelinated nerve fiber devoid of myelin by the author:

- 1) Betz interceptions
- 2) interceptions of Ranvier
- 3) interceptions by Purkinje
- 4) Schwann interceptions

98. What nerve fiber conducts an impulse with a speed of up to 120 m / s?

- 1) myelin
- 2) myelin-free
- 3) elastic
- 4) collagen

99. Name the glial macrophage by the author:

- 1) Purkinje cells
- 2) Betz cells
- 3) Gorteg cells
- 4) Schwann cells

100. Specify the glial macrophage:

- 1) oligodendroglia
- 2) astroglia
- 3) ependymoglia
- 4) micr

Abstract Topics in Cytology, Histology and Embryology
II SEMESTER

1. The history of the creation of a light microscope. Formation of histology as a science. Possibilities of electron microscopy.
2. The history of the doctrine of the cell. Modern provisions of cell theory. Contribution of T. Schwann, M. Schleiden, R. Virchow to the development of cell theory.
3. The structure and functions of the nucleus.
4. Eu- and heterochromatin. Significance for the diagnosis of the functional state of cells. The structure and function of biological membranes.
5. Organelles of synthesis. Endoplasmic reticulum and ribosomes. Structure and function.
6. Golgi apparatus. Structure. Functions.
7. Apparatus for power supply of the cell. Mitochondria. Structure. Functions.
8. Organelles of movement.
9. Fibrillar-contractile structures of the cell.
10. Peroxisomes. Structure, origin, function.
11. Lysosomes. Structure. Functions.
12. Modern ideas about the life cycle of the cell.
13. Regulation of the cell cycle.
14. Apoptosis.
15. Intercellular contacts. Types. Structure. Functions.
16. Mitosis. Contemporary views. Disturbances of mitosis.
17. Polyploidy. Concept, mechanisms of development, biological significance.
18. The structure and function of the basement membranes.
19. Histological characteristics of the glandular epithelium.
20. The blood system is normal and with various diseases.
21. Hematopoietic stem cells.
22. Macrophages. Origin, structure, function.
23. Neutrophils. Structure. Functions. Role in the body in pathology.
24. Platelets. Origin. Structure. Functions. Role in the body.
25. Development and heterogeneity of mast cells. Morphological and functional characteristics.
26. Classic "macrophages and dendritic cells. Development.
27. Morphology. Functions. Development, heterogeneity, morphofunctional characteristics of fibroblasts.
28. Structure, biosynthesis and fibrillogenesis of elastin.
29. The main substance of connective tissue. Basic substance components and their functions.
30. Histogenesis, structure and function of brown adipose tissue.
31. Physiological and reparative regeneration of the striated
32. muscle tissue. Stimulation of regeneration. Histochemical and structural aspects of the functioning of the contractile apparatus of striated muscle tissue. Adaptation of skeletal muscle tissue to various types of physical activity.
33. Smooth muscle tissue. Types. Histophysiology. Regeneration.
34. Striated muscle tissue. Views. Structure. Functions.
35. Cardiomyocyte. Types. Ultrastructure. The mechanism of contraction of working cardiomyocytes. Histogenesis of striated and smooth muscle tissue.
36. Age-related changes in muscle tissue.
37. Pathology of striated muscle tissue. Muscular dystrophy.
38. Morphofunctional characteristics of synapses. Regeneration. Pathomorphology.
39. Regeneration and age-related changes in the nervous tissue.
40. Histogenesis, structure and function of neuroglia.
41. Sources of development and histogenesis of nervous tissue.
42. Morphofunctional characteristics of receptors.
43. Blood-brain barrier.

44. Myelogenesis. Morphofunctional characteristics of myelinated nerve fibers. Development and morphofunctional characteristics of myelin-free nerve fibers.
45. Morphofunctional characteristics of the neuron.
46. Cytoarchitectonic of the cerebral cortex. Modular organization of cortex zones. Development of the cerebral cortex.
47. Development, neuronal and synaptic organization of the cerebellum. Myeloarchitectonic.
48. Histological structure and functional characteristics of the olfactory organ.
49. Olfactory analyzer. Histogenesis, regeneration and age-related changes in the olfactory organ.
50. Vomeronasal organ.
51. Visual analyzer. Structure. Functions.
52. Theories of visual perception. Visual impairment.
53. The structure of the retina.
54. The membranes of the eye. The structure and function of the cornea.
55. The membranes of the eye. The structure and function of the retina.
56. The structure of the organ of Corti.
57. Auditory analyzer. Theories of sound perception.
58. Auditory analyzer. Hearing impairment.
59. The role of hearing in the life of animals.
60. The organ of balance. Structure. Functions.
61. Mast cells and their role in the body.
62. Fibroblasts and their role in the body.
63. Hemopoiesis. Mechanisms. Regulation.
64. Features of hematopoiesis in different species of animals.
65. Immunological aspects of apoptosis.
66. Lung macrophages and their functions.
67. Features of immunological regulation of embryogenesis.
68. Critical periods of development. Abnormalities in fetal development.
69. Types of placentas.

Abstract Topics in Cytology, Histology and Embryology III SEMESTER

1. Histogenesis and morpho functional characteristics of the intestinal epithelium.
2. Histogenesis and morpho functional characteristics of the epidermis. Keratinization. Development of the heart. Cardiomyocytes. Regeneration. Age-related changes.
3. Features of the structure and development of arteries.
4. Features of the structure and development of veins.
5. Features of the structure and development of lymphatic vessels.
6. The role of the lymphatic system in the life of the animal.
7. Conductive system of the heart.
8. Morphological features of microcirculation pathways and their formation in ontogenesis. Neurohumoral regulation of blood circulation.
9. Relationship lymphatic and venous bed.
10. Adventitial cells and their role in the body.
11. Participation of cells in immune reactions. Cellular and humoral immunity. Features of the human immune system. Mediators of immune processes.
12. Morphology and development of chromaffin tissue.
13. Hypothalamic-pituitary neurosecretory system. Structure and development.
14. Hypothalamic-pituitary neurosecretory system.
15. Interaction of the pituitary gland and the hypothalamus.
16. Thyroid hormones. Education, impact on the body under conditions of norm and pathology.
17. The use of hormonal drugs in animal husbandry. Blood supply to the pituitary gland.
18. APUD system. Structure. Origin. Functions.

19. Development, structure and histophysiology of teeth.
20. Lymphoepithelial pharyngeal ring of Pirogov.
21. Gastroenteropancreatic endocrine system. Development. Structure. Functions. Islets of Langerhans. Development. Structure. Functions.
22. Histophysiology of hepatocytes.
23. Compensatory and adaptive processes in the intestine.
24. Glands of the oral cavity. Structure. Functions.
25. Morphological features of intestinal lymphoid (Peyer's) plaques. The appendix, structure, role in immunogenesis.
26. The structure of the mucous membrane of various parts of the stomach. Protective role of the gastric mucosa. The role of dysfunction of the gastric mucosa in the development of diseases of the gastrointestinal tract.
27. APUD-system. Structure. Origin. Functions. APUD system and digestion. The histological structure of the bronchial tree. Features of the structure of small bronchi. Features of the structure of the lungs in the age aspect.
28. The lungs are an immune organ. The structure of the location and cellular composition of immune structures in the lungs. Respiratory section of the lungs. Structure, cellular composition, functions of cells. Air-blood barrier. Structure. Functions.
29. Surfactant, structure, function.
30. Neuroendocrine system of the respiratory system (APUD-system).
31. Renin - Angiotensin - Aldosterone system. The role of the lungs.
32. Skin as an organ of the immune system.
33. Physiological and reparative regeneration.
34. Morphofunctional characteristics of specialized cells of the epidermis. The effect of retinoids on the regeneration and functional state of the skin.
35. Mechanisms of the barrier-protective functions of the skin.
36. Histological structure and functional characteristics of the sebaceous glands. Seborrhea (clinical histology).
37. Histological structure and functional characteristics of the sweat glands. Histological structure and functional characteristics of hair. Pigmentation. Cyclic activity of hair follicles.
38. Skin regeneration.
39. Derivatives of the skin.
40. Aspects of development, regeneration and neurohumoral regulation of the mammary glands.
41. Development and histological structure of nails.
42. Hormonal regulation of the female reproductive cycle. The biological effect of sex hormones on the body.
43. Cyclic changes in the organs of the female reproductive system.
44. Hemo-placentals barrier.

Enumeration of the types of appraisal tools.

Test.

Interview.

Diagnostics of the micropreparation.

Situational task.

Report with presentation.

Abstract.

TEST SCALE

One test item contains 10 closed-ended questions for assessment - "know".

The student must remember that for one test question out of the four indicated answers, choose the only correct one. For each correct answer - 10%. The overall test score is defined as the sum of the percentages earned.

INTERVIEW RATING SCALE

№	Indicator name:	Mark in%
The form		0-80
1.	deep and solid assimilation of the material of the section;	0-20
2.	complete, consistent, competent and logically stated answers;	0-20
3.	demonstration by the student of knowledge in the volume of the passed program and information from additional literature;	0-20
4.	reproduction of educational material with the required degree of accuracy.	0-20
ANSWERS ON QUESTIONS		0-20
TOTAL		100%

DIAGNOSTIC RESPONSE SCALE FOR MICROPREPARATION

The mark is set on a 100-point scale and corresponds to the number of correctly identified slides. An unsatisfactory mark received by a student on a test must be retaken until he receives a positive mark.

Guidelines for assessing the response by microscope preparations.

85-100 points are awarded if the student:

- a) identified the drug and gave a complete answer according to the plan;
- b) correctly completed the tasks for the diagnosis of histological micro preparations, gave comprehensive information showing in-depth knowledge on this issue (with examples).

70-84 points are awarded if the student:

- a) identified the drug, answered all the questions according to the plan, but made inaccuracies and minor mistakes;
- b) 80% of the theoretical material is covered or minor mistakes were made when performing tasks for the diagnosis of histological micro preparations. gave comprehensive information showing in-depth knowledge on this issue (with examples).

60-69 points are awarded if the student:

- a) identified the drug, but did not fully answer;
- b) 60% of the material is covered or gross errors were made when performing tasks for the diagnosis of histological micro preparations.

59 or less is awarded if the student:

- a) did not identify the drug
- b) less than 50% is covered or gross errors were made when filling out the tasks of the IWS on diagnostics of micro preparations.

THE SCALE OF EVALUATION OF THE SITUATIONAL PROBLEM SOLUTION

A situational task (assessment of “own”) consists of a condition and a task of 3-5 histological questions. The overall score is defined as the sum of the scores for the results.

№	Indicator name:	Mark in%
1.	When answering questions, the ability to analyze information was demonstrated;	0-25
2.	the ability to synthesize new information has been demonstrated;	0-25
3.	explanations are given and reasonable conclusions are made based on the interpretation of information;	0-25
4.	cause-and-effect relationships are established, regularities are revealed.	0-25
TOTAL		100%

ШКАЛА ОЦЕНИВАНИЯ ДОКЛАДА С ПРЕЗЕНТАЦИЕЙ

№	Indicator name:	Mark in%
1.	The relevance and relevance of the material to the chosen topic in the discipline under study.	0-10
2.	<ul style="list-style-type: none"> • information sufficiency: the presence of a logical structure for constructing a presentation: • introduction with problem statement; • the main part, divided by main ideas; • conclusion with conclusions obtained as a result of reasoning. 	0-25
3.	Style and language of presentation: (appropriate use of terminology, clarification of concepts, diagrams, conciseness, consistency, correct application and design of quotations, use of professional terms, stylistic construction of phrases, etc.).	0-20
4.	The adequacy and number of sources of information used.	0-10
5.	Aesthetic design of the work (neatness, use of MS PowerPoint, text formatting, highlighting, use of diagrams, drawings, diagrams and animations, etc.)	0-20
6.	The presence of an expressed own position, including when answering questions.	0-10
7	Compliance with the regulations.	0-5
TOTAL		100%

INTERMEDIATE CONTROL RATING SCALE

One test item contains 30 closed-ended questions for assessment - "know".

The student must remember that for one test question out of the four indicated answers, choose the only correct one. The overall score for the test is determined as the sum of the collected percentages from 20 to 30 according to the Technological map of the discipline (Attachment 7):

20 - 23 – «satisfactory»;

24-27 – «good»;

28-30 – «excellent».

**TECHNOLOGICAL MAPS to «Histology, embryology, cytology».
«Medical»**

II SEMESTER

Name of modules	Control	form of control	Scoring minimum	Scoring maximum	schedule of control (semester, week)
Rating control 1.					
Cytology. Embryology.	Current control	Attendance is considered. Students' independent work (SIW): essay / presentation on the topic of the lesson. Testing, interview on questions, description of micropreparation.	3	5	27
	Mid-term control	Testing.	10	20	
Rating control 2.					
The general histology.	Current control	Attendance is considered. Students' independent work (SIW): essay / presentation on the topic of the lesson. Testing, interview on questions, description of micropreparation.	3	5	37
	Mid-term control	Interview	24	40	
Total			40	70	
Intermediate control. CREDIT.			20	30	
Semester rating by discipline.			60	100	

Note:

1. For each of the missed and not worked out practical lessons or lectures, 0.5 points are deducted.

III SEMESTER

Name of modules	Control	form of control	Scoring minimum	Scoring maximum	schedule of control (semester, week)
Rating control 1.					
The nervous system. Sensory system. The cardiovascular system. Organs of hematopoiesis and immune defense. Endocrine system.	Current control	Attendance is considered. Students' independent work (SIW): essay / presentation on the topic of the lesson. Testing, interview on questions, description of micropreparation.	3	5	4
	Mid-term control	Testing.	8	15	
Rating control 2.					
Digestive system.	Current control	Attendance is considered. Students' independent work (SIW): essay / presentation on the topic of the lesson. Testing, interview on questions, description of micropreparation.	3	5	9
	Mid-term control	Interview.	8	15	
Rating control 3.					
Respiratory system. Skin and its derivatives. Urinary system. Male reproductive system. Female reproductive system.	Current control	Attendance is considered. Students' independent work (SIW): essay / presentation on the topic of the lesson. Testing, interview on questions, description of micropreparation.	3	5	15
	Mid-term control	Colloquim.	9	15	
Rating control 4.					
Human embryology.	Current control	Attendance is considered. Students' independent work (SIW): essay / presentation on the topic of the lesson. Testing, interview on questions, description of micropreparation.	3	5	18
	Mid-term control	Testing.	3	5	
Total			40	70	
Intermediate control. Exam.			20	30	
Semester rating by discipline.			60	100	